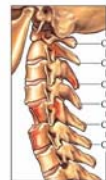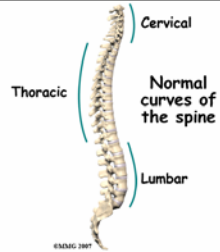


Spine Injury Clearance in Children



Thomas V Whalen MD



- “The c-spine is cleared when the clinician is satisfied, after appropriate history, examination, and investigation, that the risk of an important injury being present is **negligible**.”

NEGLIGIBLE

- Main Entry: neg-li-gi-ble
- Function: *adjective*
- Etymology: Latin *neglegere, negligere*
- Date: 1829
- **so small or unimportant or of so little consequence as to warrant little or no attention**
- ...within the *margins for error* that have been agreed to be acceptable in this case

- Low incidence
- Age-related factors to consider

Causes

- Motor vehicle collisions (Generally < 8 YO)
- Athletics (Generally > 8 YO)

Background

- Uncommon: 1 to 2% of multiply injured children
 - But 60 to 80% of such injuries are cervical (30 to 40% in adults)
- Major Trauma Centers may therefore see one or two such injuries each year
- Neurologic sequelae are *relatively* uncommon

Anatomical – Developmental Distinctions

- Relatively large head of the infant and toddler with underdeveloped neck musculature
 - more susceptible to hyperflexion - extension injuries.
- Incomplete ossification
- Different vertebral configuration
- Ligamentous laxity
- These differences are largely eliminated by age eight

Patterns

- Younger children with higher cervical spine injuries and higher incidence of non-bony injuries
 - Fulcrum of cervical motion is much higher (C2–C3) in young children than in adolescents and adults (C5–C6)
 - Articulating facet joints in young children are more horizontally oriented, leading to greater spine mobility and less stability, which is also responsible for the relatively high incidence of C-spine injuries without radiographic abnormalities in that age group

Patterns

- In children less than 8 YO there is a rather high mortality rate, due to significant concomitant head injuries


Raising the Stakes

- Challenge to examiners because of their highly variable ability to participate in the clinical examination and their unpredictable radiographic skeletal appearance because of differing levels of maturity

Evaluation


Evaluation

- **CONTROVERSIAL**





Evaluation & Management

- Pre-hospital C-spine precautions with regular C-spine immobilization
- C-spine radiographs
- Based on the rate of C-spine injuries without radiographic abnormalities, children with an altered mental state and significant trauma history should be assumed to have a cervical cord injury
 - CT
 - MRI
 - Examination




Pseudosubluxation

- Pediatric pseudosubluxation refers to normal mobility of C-2 on C-3 in flexion which may be so pronounced as to be mistaken for pathologic motion; (is normal in children < 8 years old);


"Clearing the cervical spine of paediatric trauma patients"

- Emerg Med J 2004;21:189–193.
- "Emergency physicians are the first to assess and manage traumatised patients, including children."




"Clearing the cervical spine of paediatric trauma patients" – Examination

- 1. no midline cervical tenderness
- 2. no focal neurological deficit
- 3. normal alertness
- 4. no intoxication
- 5. no painful, distracting injury
- From the NEXUS Study, NEJM, 2000




Syndrome of Spinal Cord Injury w/o Radiographic Abnormality

- Accounts for up to 2/3 of severe cervical injuries in children < 8 years of age
- Inherent elasticity in pediatric cervical spine can allow severe spinal cord injury to occur in absence of x-ray findings
- Fracture through the cartilaginous end plates (which are not visualized by x-rays), may be among the causes of this injury
- MRI may give a more anatomic diagnosis by showing hemorrhage or edema of the spinal cord





The Best Approach?

- "Patients in a very young age group who are incapable of participating in a meaningful interactive evaluation because of a variety of reasons (cognitive impairment or emotional distress) may benefit from early fluoroscopy, using traction, and flexion-extension evaluation by an experienced examiner to assess for ligamentous instability, rather than proceeding with MRI scanning and its associated management needs (including intubation) and resultant occasional diagnostic ambiguity with regards to ligamentous signal abnormalities."
- J Trauma Editorial Comment, 2007



J Trauma Comment, Continued

- “Further, pooling of relevant data through a multicenter effort for a prolonged period of time may provide more meaningful epidemiologic data for the development of future trauma care algorithms for pediatric spinal injuries.”



Costs of Diagnostic Tests

- Xray: \$325
- CT: \$550
 - Radiation risk in the child
- MRI: \$2500



NEGLIGIBLE

- Main Entry: neg·li·gi·ble
- Function: *adjective*
- Etymology: Latin *neglegere, negligere*
- Date: 1829
- **so small or unimportant or of so little consequence as to warrant little or no attention**
- ...within the *margins for error* that have been agreed to be acceptable in this case

