Severe Influenza and superimposed Streptococcal Pneumonia-Induced ARDS in a Young Patient: Escalation to ECMO Support

Kaur,Loveneet, IM Resident

AtlantiCare Regional Medical Center, Atlantic City, N.J., U.S.A.

Introduction

ARDS (Acute Respiratory Distress Syndrome) is a critical condition characterized by severe hypoxemia and impaired gas exchange, often requiring advanced therapeutic interventions.
This poster highlights a rare and life-threatening case of ARDS induced by severe influenza virus infection and superimposed Streptococcus pneumonia pneumonia.

Case Description

- 44-year-old male with known history of prior opiate abuse on Suboxone, history of anxiety, obesity presented to hospital for progressive shortness of breath, cough symptoms of 3 to 4 days duration.
- He started having initial upper respiratory infection symptoms followed by symptoms of cough, chest tightness, mucus expectoration associated with fever, chills and bodyaches.
- In ED, patient was hypoxic on room air due to which was placed on nonrebreather mask subsequently placed on BiPAP due to increased work of breathing and hypoxia.
- On physical examination, bilateral coarse breath sounds, rhonchorous, reduced bilaterally.

Initial Findings

- Tested positive for influenza A
- Initial ABG on arrival 7.24/38/76/16 on 100% BiPAP
- Urine drug screen positive for amphetamines and benzos
- Lactate elevated at 6.49, downtrended to 4.2 s/p Sepsis bolus
- Creatinine 2.83 > 2.61, Potassium 6.6 >6.4, Bicarbonate of 18
- Streptococcal pneumoniae urine antigen tested positive.

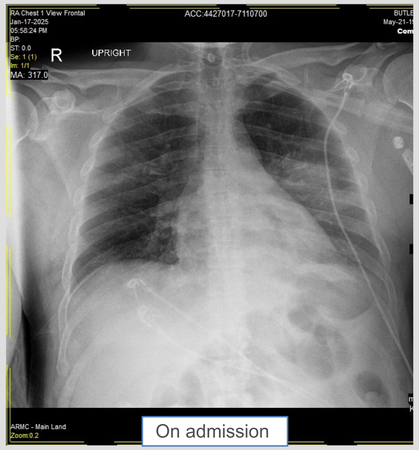

On admission

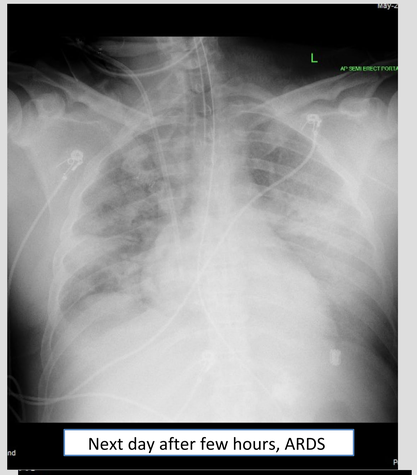

Next day after few hours, ARDS

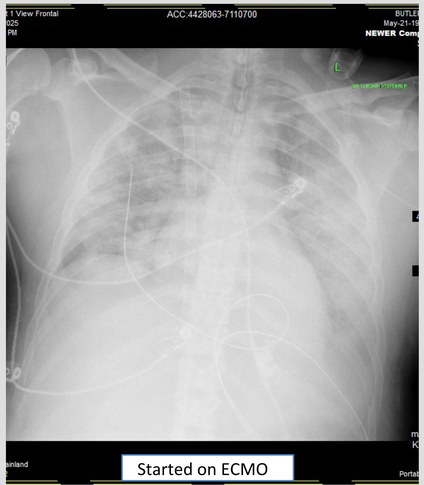

Started on ECMO

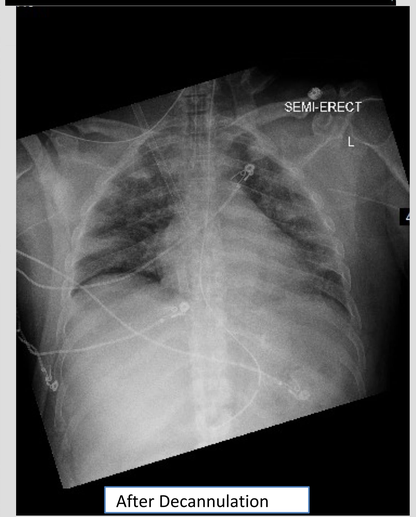

After Decannulation

Hospital Course

- Chest x-ray on admission revealed left upper and lower lobe pneumonia
- Started on Steroids, Ceftriaxone and doxycycline along with Tamiflu
- MET (next morning)- severe hypoxia tachypnea, tachycardia on BiPAP >intubated > hypoxic PEEP increased to 12 and FiO2 to 100%, ARDS (X-ray, worsening B/L Infiltrate
- Persistent hyperkalemia, metabolic acidosis, CVVHD was started, stopped day 2
- Proning along with Flolan on vent FiO2 100% as deteriorated within few hours

>unsuccessful >Continuous PaO2 of 50-52 FiO2 of 100% and PEEP of 14 > started on VV ECMO (right femoral-left femoral due to difficult wire placement in right IJ)

- VV ECMO changed to right IJ-right femoral vein to reduce recirculation & better lung rest.
- ABG 7.49/42/88/25 on VV ECMO 70% and ventilator PRVC 14/320/40/12
- ECMO settings and FiO2 on vent reduced based on ABGs daily with significant improvement
- Day 6, VV ECMO decannulated
- Day 7 liberated from mechanical ventilation, transitioned to nasal cannula

Conclusion

The synergistic effect of Flu with superimposed bacterial infection can rapidly worsen respiratory function, overwhelming the lung's ability to oxygenate blood, and leading to the need for extracorporeal membrane oxygenation . ECMO, an advanced life support technique, provides temporary circulatory and respiratory support to patients with refractory respiratory failure.
ECMO provided significant improvement In ARDS in this patient by allowing lungs to rest and recover.