An uncommon presentation of a rare disease: Membranous-like glomerulopathy with masked IgG kappa deposits (MGMID)

Zedrick Aguirre, M.D., Sahil Mamtani, M.D., Nitin Behl, M.D., Jay Shastri, D.O.
AtlantiCare Regional Medical Center

Introduction

Membranous-like glomerulopathy with masked IgG kappa deposits (MGMID) is a rare glomerular disease characterized by glomerular immune deposits that are not detected on routine immunofluorescence (IF) but appear on paraffin IF. On Electron Microscopy, deposits stain for IgG kappa light chains and are usually subepithelial or mesangial. The disease primarily affects females under 40 and typically presents with nephrotic-range proteinuria, hematuria, and preserved complement levels. PLA2R antibodies are consistently negative. Although some patients have positive autoimmune serologies, MGMID is not clearly autoimmune in nature.

Case

A rare case of MGMID in a 77-year-old male with paroxysmal atrial fibrillation, CAD s/p CABG, mechanical aortic valve replacement, and progressive CKD. He presented with worsening renal function, microscopic hematuria, and 24-hour urine protein of 3.2 g/day and was being evaluated for SLE. Serologic workup showed indeterminate anti-dsDNA, initially negative ANA (later repeated as positive), low C3/C4, and positive antiphospholipid antibodies. Due to thrombocytopenia, a renal biopsy was delayed, and he was given IV dexamethasone and IVIG. Once stabilized, biopsy confirmed MGMID. Coincidentally, renal function improved with IVIG and steroids. After in hospital treatment, he was discharged on mycophenolate mofetil for ongoing immunosuppression.

Examples

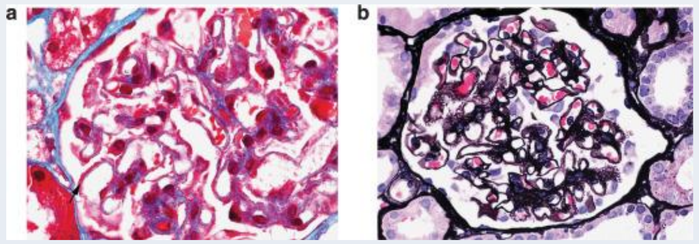

Figure 1. Glomerular deposits in membranous-like glomerulopathy with masked IgG-κ deposits (MGMIDs). (**a**) Masson trichrome stain (**b**) Segmental spikes present along the glomerular basement membranes by Jones methenamine silver stain.

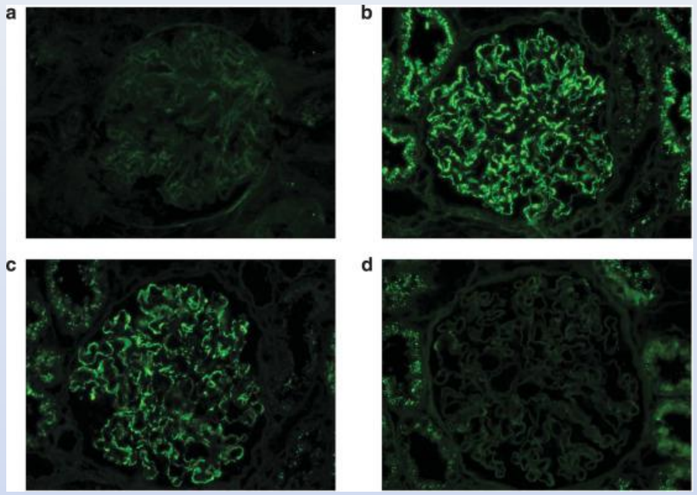

Figure 2. Immunofluorescence findings from membranous-like glomerulopathy with masked IgG-κ deposit (MGMID)

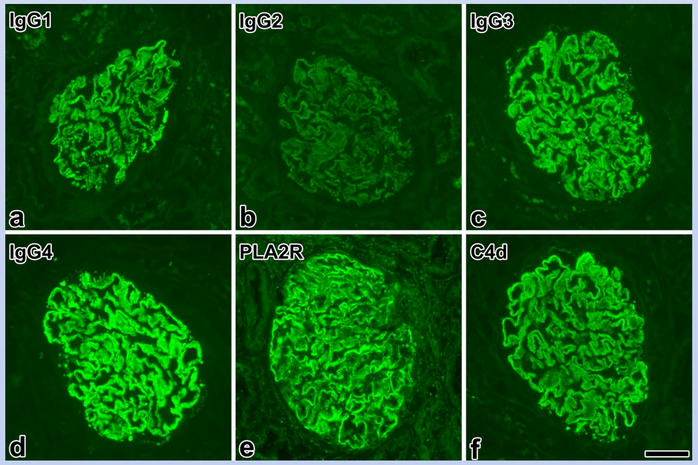

Figure 3. Immunofluorescence findings of primary membranous glomerulopathy

Conclusion

This case highlights an atypical presentation of MGMID in an elderly male. While the disease classically affects young females, this patient demonstrated typical clinical and histologic findings. The presence of autoimmune markers raises questions about a potential immune-mediated component, though definitive mechanisms remain unclear. There is no established treatment, and reported therapies include RAAS blockade, steroids, and immunosuppressants with variable outcomes. Although our patient received steroids, IVIG, and mycophenolate for SLE, incidentally, the MGMID improved as well. As MGMID is increasingly recognized, broader age and gender presentations may become apparent, and further studies are needed to define optimal management strategies.

References

Larsen, C.P., et al. “Clinicopathologic Features of Membranous-Like Glomerulopathy With Masked IgG Kappa Deposits.” Kidney International Reports, no. 4, Elsevier BV, Nov. 2016, pp. 299–305. Crossref, doi:10.1016/j.ekir.2016.08.012.

Larsen, Christopher P., et al. “Membranous-like Glomerulopathy with Masked IgG Kappa Deposits.” Kidney International, no. 1, Elsevier BV, July 2014, pp. 154–61. Crossref, doi:10.1038/ki.2013.548.

Bajcsi, Dóra, et al. “The Value of PLA2R Antigen and IgG Subclass Staining Relative to Anti-PLA2R Seropositivity in the Differential Diagnosis of Membranous Nephropathy.” BMC Nephrology, no. 1, Springer Science and Business Media LLC, Aug. 2023. Crossref, doi:10.1186/s12882-023-03273-4.